

TRANSACTIONS OF THE PHILADELPHIA ACADEMY OF SURGERY

Stated Meeting Held February 7, 1927

The President, DR. CHARLES F. MITCHELL, in the Chair

BONE TRANSPLANTATION FOR SPONDYLOLISTHESIS

DR. A. BRUCE GILL presented three cases of spondylolisthesis which had been operated on by bone transplantation to fuse the three lower lumbar vertebræ with the sacrum.

DOCTOR GILL also presented a series of lantern slides illustrating: Osteochondritis of the hip (Legg's disease). Osgood-Schlatter's disease of the tubercle of the tibia. Koehler's disease of the tarsal scaphoid. Freiberg's disease of the head of the second metatarsal bone. Displacement of the epiphysis of the head of the femur during adolescence. Osteochondritis of the bodies of the vertebræ. Apophysitis of the heel.

OSTEOCHONDRITIS OF HIP

DR. E. L. ELIASON reported the history of a girl, aged eleven, who early in July, 1926, without apparent injury, began to limp but without pain. She continued to limp for six weeks, at which time an X-ray was made and reported negative. She continued to limp until December 23, when, following a slip on the ice, she was unable to rise due to disability in her left leg. On admission to the hospital, December 28, 1926, an X-ray revealed an epiphyseal separation at the upper end of the femur. Examination of her previous X-ray taken in August, disclosed the fact that a slight slipping of the epiphysis could be noted at that time. Fluoroscopic reduction was obtained and the limb placed in a Whitman abduction case, in which it was kept for five weeks. At this time it was removed and an X-ray taken which showed perfect reduction but also a rarefaction of the upper end of the diaphyseal fragment. This patient ran a persistent fever of from 99 to 99.2 or 99.3 during her stay in bed. Her leucocytes were between 10,000 and 11,000. Diagnosis: Osteochondritis with complete separation of the epiphysis. Patient is still in hospital.

DOCTOR ELIASON gave the history of a second child, a boy, aged thirteen, who was well until a month ago, when he was struck on the left hip by himself with a hammer while doing some nailing. Following this he had some pain but was able to walk without limping. A few days later he began to limp and continued to do so up until about two weeks before his present accident, which occurred October 10, 1926. On this date, while walking along on the level ground, the patient's left leg rotated itself externally and he fell to the ground backwards. He was picked up and helped home, being unable to stand on this leg. He was admitted to the hospital eight days after his accident, at which time X-ray revealed an epiphyseal separation at the upper end of the femur. Reduction was accomplished under the fluoroscope and the limb dressed in a Whitman case. Throughout the patient's stay in the hospital he ran a slight temperature—average 99. A leucocyte count was

not made. At the end of seven weeks the case was removed and an X-ray showed a perfect reduction and union, there being, however, some rarefaction and absorption on the upper end of the diaphysis. The radiologist states that at this time he cannot be sure whether this rarefaction is due to the injury and disuse or some preëxisting disease. Diagnosis: Osteochondritis with complete separation of the epiphysis.

Patient has completely recovered but is still under observation.

DR. W. G. ELMER said that he had at present a child of fourteen years, who fell while roller skating last September. She was treated in the general surgical service of one of our large hospitals for an intracapsular fracture of the hip, by means of an abduction plaster case from the ankle to the waist. The child still limps and has some pain when she walks without a crutch. The X-ray shows no union and the head of the femur is pushed down on the neck. There is shortening of approximately one inch. Intracapsular fracture of the hip is very unusual in a child. If the bone had been normal there should have been solid union in five weeks if the fragments had been in good position and the X-ray taken at the time the case was applied showed that they were in good position. There was evidently some fault in the texture of the bone and this case should be classed as osteochondritis deformans juvenilis or Legg's disease. The speaker does not favor bone pegging in these cases as the bone is of poor quality to start with. Abduction in plaster and protection from weight-bearing for six months is his method of treatment.

Another patient, a boy of seventeen years, was hurt in a foot-ball game, but continued in the game and continued playing during the remainder of the season, although he walked with a limp. He had been having chiropractic treatments from the autumn of 1924 to the autumn of 1925. His physician then had an X-ray examination made and also an examination by a surgeon and the diagnosis then made was tuberculosis of the hip. When first seen by Doctor Elmer in January, 1926, there was no muscle spasm, the hip moving freely in all directions, but with range of motion somewhat limited, and there was one-half inch shortening. The epiphysis was separated from and pushed down on the neck of the femur. A diagnosis of Legg's or Perthe's disease was made. A good result was obtained in this case after treatment over one year.

POST-OPERATIVE STRICTURE OF THE COMMON BILE-DUCT

DR. EDWARD J. KLOPP said that accidental injury of the common bile-duct with the resulting biliary fistula or stenosis and the evolution of the methods devised for the correction of these sequels are well known to most surgeons of experience. Fistula and stenosis occasionally follow purposive operations upon the common duct when there has been no error in technic. Obstruction may be avoided by burying a catheter in the duct extending into the duodenum as recommended by Duval and Richard. Their method is comparatively simple and should receive serious thought when drainage of the common duct is desired in the absence of infection. The T or fishtail tube is used because it is practical and easily introduced. In many cases a large amount of bile leaks around the tube. It may do no harm in the majority of cases but we cannot deny that it has caused serious damage.

The use of the buried catheter in reconstructing the common bile-duct as suggested by McArthur has given him and others gratifying results. He

POST-OPERATIVE STRICTURE OF THE COMMON BILE-DUCT

recommends leaving the catheter long so that the intestinal tug will cause it to be discharged through the bowel after the duct has been repaired and epithelialized, and before there has been bile deposit about the tube to again produce obstruction. Short tubes may remain for an indefinite period and act as a nidus for deposit of bile salts.

Various plastic operations have been performed on the ducts many of which met with success. Eliot wrote a splendid paper in 1918 reporting three of his own cases and abstracting many cases from the literature and personal communications. It gives one a comprehensive idea of the various methods employed in plastic surgery of the biliary apparatus. The more recent paper by Walters adds valuable information regarding this work.

Needless to state that most of the cases reported have been dealt with satisfactorily. It is regrettable that more failures have not been reported. The Van den Burgh test has been a great aid in selecting a comparatively safe time when one might undertake to correct a stricture

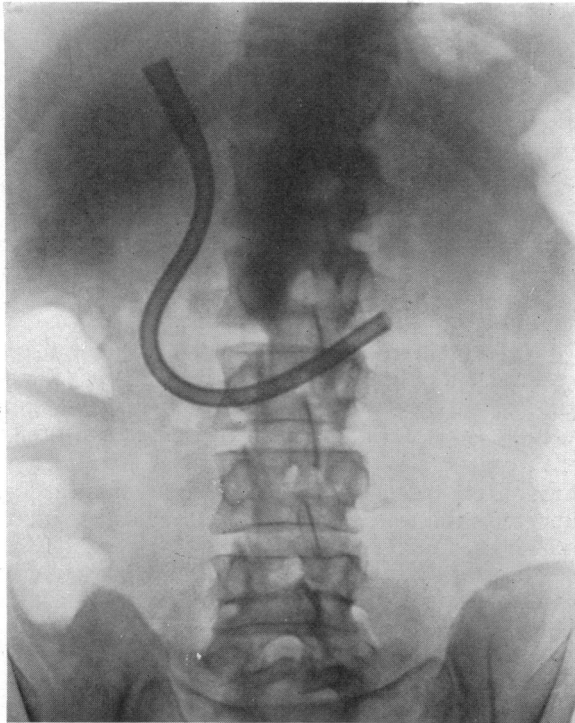


FIG. 1.—Showing part of a No. 24 French Catheter which has been in the repaired common duct and the duodenum for ten months. The patient is practically free from symptoms.

of the common duct. In the absence of fistula and the increase of bile pigment in the blood, it has been suggested that a fistula be established and correction of the stricture be done at a second operation. These cases are not select operative risks; the operation is time-consuming on account of adhesions and generally the absence of the gall-bladder as a guide. The following case is reported because of several impressive facts:

1. The common duct was injured while removing a gall-bladder that was not badly diseased.

2. The use of the fishtail tube in the first reconstructive operation was followed by stricture within six months.

3. Introduction of the buried catheter through the papilla of Vater and sphincter of Oddi was accomplished with considerable difficulty at the second reconstructive operation, due to the large size catheter.

4. The patient has worn the catheter for approximately ten months with little discomfort. One is amazed at the tolerance of the duct and the duodenum. We think the catheter should be removed through the intestine, probably jejunum. The patient declines interference so long as he is comfortable. It is feared that there will be a deposit of bile and subsequent obstruction.

A man, aged thirty-six; referred to Doctor Gibbon's service, Jefferson Hospital, by Doctor Immerman of the Gastro-enterological Department, August 24, 1925. The gall-bladder and appendix were removed elsewhere on April 4, 1925, for symptoms referable to the stomach and intestines with pain radiating under his right shoulder and back. Two drains were inserted. Three days later one drain was removed which was followed by profuse drainage of bile. Three weeks after the operation re-suture of the wound was attempted. There was profuse drainage of bile until six weeks before admission to Jefferson.

On admission there was marked jaundice with all the usual phenomena. There was a large fluctuating mass bulging in the region of the old scar. This was opened by the resident who obtained 1000 c.c. of bile. The jaundice faded, bile drained freely through the fistulous opening and the direct Van den Burgh was negative three weeks later.

On September 18, 1925, under ether anaesthesia, we injected the fistulous tract with methylene blue and excised the old abdominal scar and fistula. An obstructing scar 1 cm. long in the mid-portion of the common duct was partially excised and a fishtail tube inserted in the usual manner. A Penrose drain was placed along the side of the tube. Bile immediately drained through the tube; on the eighth day there was free drainage external to the tube. On the fourteenth day the tube came out. He was discharged, wound healed, no jaundice, digestion good, bowels satisfactory, on October 29, 1925.

He was symptom-free until March 1, 1926, when jaundice reappeared with the associated symptoms. Wound remained closed; no swelling of abdomen. He returned to the hospital, March 8, 1926; was transferred to the Pennsylvania Hospital, March 21, 1926, where I was then active. After careful preparation he was again operated upon April 12, 1926, under ether anaesthesia. The scar in the duct was 2 cm. long extending to the duodenum. It was excised. After dilating the papilla and sphincter of Oddi a No. 10 soft rubber catheter passed into the duodenum. We were desirous to bury a large catheter, having failed previously to prevent stricture. The duodenum was opened and more dilating was done with suitable instruments. It seemed as if a No. 24 catheter, the size we decided to use, should pass. We were unable to grasp the tip of the catheter through the sphincter with a duct stone forceps. The No. 10 catheter was introduced through the distal portion of the duct into the duodenum. The eye-end of the larger catheter was sutured in the funnel-end of the smaller and by pulling on it through the artificial duodenal opening and pushing on the larger from above it was put in position with comparative ease. A suitable mandrin was not at hand. The funnel extended upward into the dilated portion of the duct. It was impossible to make a satisfactory anastomosis of the duct. The defect was covered with omental tissue.

About 10 cm. of the distal end of the catheter was cut off. It was thought that too much catheter of large calibre in the small intestine might be very uncomfortable. I now think that this was an error. The duodenal wound was closed. A Penrose drain was carried to the site of duct anastomosis.

ACUTE INTESTINAL OBSTRUCTION

Bile drained externally for three weeks. There has been no drainage since. The scar is satisfactory; there is no evidence of hernia.

DR. JOHN B. DEAVER said that with the patient he agreed that it is better to continue to wear the tube. Doctor Deaver has had the tube remain as long as eighteen months, and then be passed. The tugging probably has little to do with this. One patient wore a T-tube for four years. The most satisfactory operation when feasible is anastomosis of the proximal end of the common duct to the duodenum. This is not a difficult operation and offers excellent results. However, it was not possible for Doctor Klopp to do this in this case. It sometimes requires two or three operations to secure a result in this type of case with always a chance of subsequent stricture.

PRIMARY ULCER OF THE JEJUNUM

DR. I. S. RAVDIN read a paper with the above title, for which see page 873.

ACUTE INTESTINAL OBSTRUCTION

DR. J. STEWART RODMAN reported three cases which had occurred during the past year in his service at the Bryn Mawr Hospital. In each case the cause of the obstruction was sufficiently unusual to warrant placing it on record.

CASE I.—A woman, age fifty, was admitted to the hospital, November 28, 1925, with the chief complaint of "pain in abdomen and vomiting." About twelve hours before admission she was suddenly seized with severe pain in the lower abdomen followed by nausea and vomiting. The pain at first was generalized throughout lower half of abdomen, later to become more localized about umbilicus. The bowels had moved the day before. Several enemas before admission had failed to give relief. The patient had had a cholecystectomy and vaginal repair eight years ago. The past history was otherwise negative. When admitted she was in acute abdominal distress. Palpation of abdomen revealed a suggestion of a mass on the right side of abdomen, although as she is quite stout, it was impossible, to be sure of this. Vaginal examination was negative for pelvic pathology. A diagnosis of acute intestinal obstruction due to adhesions from laparotomy was made. Operation revealed a large mass filling the entire right lower quadrant across middle line due to an enormously distended bowel. A puncture was made which immediately allowed a large quantity of gas to escape. The collapsed bowel was then easily delivered and as this was done the bowel was seen to rotate completely, relieving the obstruction above and below. The portion of bowel involved was the lower part of the ascending colon and cæcum. The appendix was removed and the wound closed without drainage. The patient made an uneventful recovery, leaving the hospital three weeks later. This case was obviously one of torsion at two points, one in the ascending colon, another in the terminal ileum, completely isolating and obstructing the intervening loop of bowel. A cursory review of the literature for the past ten years has failed to reveal another case of torsion at two different points of the bowel isolating and distending a loop as in this case. Acute obstruction due to torsion at a single point is, as would be expected, a fairly common occurrence.

CASE II.—A man, age sixty-eight, was admitted to the hospital, November 4, 1925, with chief complaint of "obstruction of the bowel." Six days before admission he had been suddenly seized with severe pain in the lower

left quadrant of abdomen and vomited. Morphia relieved the pain partially. On the fourth day after the onset of the illness the pain was suddenly and spontaneously relieved and the bowels moved. The pain returned the following day and enemas were ineffectual. No further vomiting occurred. The man had had a double inguinal hernia for the last twenty years for which he had worn a truss. On admission the temperature was 99.3, pulse 80, respiration 20. He was apparently in pain. The abdomen was moderately distended, resistant and somewhat tender on the left lower quadrant. No definite tumor mass was found in left inguinal canal, although the overlying tissues somewhat swollen and tender. There was a reducible hernia on the right side. Under local anæsthesia the left inguinal canal was opened. No hernia was found but a thickened and œdematous spermatic cord which traced to the internal ring disclosed a mass apparently adherent to the ring within the abdomen. The incision was enlarged upward, opening the abdomen, and a loop of small intestine found adherent to the parietal peritoneum. No attempt was made at that time to dislodge the mass, but a Paul's tube was inserted into a loop of bowel proximal to the mass. The patient made a relatively smooth recovery from the operation but two subsequent attempts to close the fecal fistula have been unsuccessful. Ileosigmoidostomy was performed nineteen days after the first operation and inversion of the fistula was made six weeks later. In spite of daily evacuations by rectum the fistula continued to drain.

Reduction of strangulated hernias *en masse* happens every now and then, but in the reported cases has always been the result of taxis. The unusual feature of this case was that no taxis was used but large and repeated doses of morphia given.

CASE III.—A man, age fifty-five, was admitted to the Bryn Mawr Hospital, January 18, 1926, with the chief complaint of pain in the abdomen. On the previous day the patient had been seized with pain in the left lower quadrant and took paregoric for relief. The pain continued on the following day, gradually increasing in severity. Vomiting occurring once. The bowels have been more or less constipated for some time, but moved slightly twenty-four hours before admission, on the second day of the illness. The patient had been in good health save that one week prior to admission he was run over by a wagon, sustaining contusions of both legs. On examination the abdomen was slightly distended and tender in lower left quadrant and there was rigidity of the left rectus. Peristalsis was about normal. No masses were felt. Temperature 98.2, pulse 60, respiration 20. At operation, the evening of admission, the intestines were found to be filled but no free fluid was present. A small mass was felt within the abdomen adherent to parietal peritoneum over the sigmoid. On further exposure the mass proved to be sigmoid somewhat kinked and adherent to parietal peritoneum by an inflammatory mass in its wall. Gentle manipulation loosened the mass from the parietal peritoneum, upon which, the sigmoid resumed its normal position. As the mass was small and did not then encroach upon the lumen of the bowel, it was not disturbed. Convalescence was uneventful except for a surgical wound infection. W. J. Mayo (*Journal American Medical Association*, September 8, 1917), in 1907 reported with Adson and Griffin five cases, of diverticulitis of the sigmoid, the first in which the pathology was established during life—since has resected bowel for diverticulosis in 42 cases—in 36 sigmoid, one transverse colon, in one the hepatic flexure and cæcum, in one the rectosigmoid juncture and in two the rectum; all acquired symptoms suggestive of acute appendicitis on left side. Mayo recognizes four types. I. Self limiting Diverticulitis and Peridiverticulitis. II. Diverticulitis

MESENTERIC CYSTS

and Peridiverticulitis with abscess resulting in Fistulæ. III. Obstruction (31 per cent. malignant disease coexists) Obstruction not quite complete therein differing from carcinoma. It is sometimes necessary to do colostomy or temporary ileostomy. IV. Carcinoma developing on a Diverticulum.

Of 42 cases operated up to time of report, 14 per cent. died as a result of operation.

J. T. Rogers (*Minnesota Medicine*, January, 1923) believes the surgical treatment in any given case must depend upon the severity of the symptoms, the condition of the patient, and the judgment of the operating surgeon. From his own experience and a careful review of many cases reported, he is convinced that simple drainage in most cases will be followed by cure. In three cases resection seemed necessary but drainage resulted in cure.

The incidence of diverticulitis of the large bowel is set forth by J. W. Larimore (*Journal Missouri State Medical Association*, April, 1925) in 4408 X-ray examinations he found 55 times (1.24 per cent.). In 21 cases there were isolated diverticula, 34 cases showed multiple diverticula. The sigmoid was the most frequently involved portion of bowel.

DR. WALTER G. ELMER recalled a patient who had complete obstruction for one week. A long median incision was made and instantly the large intestine protruded from the wound and became distended to the size of a child's balloon and seemed to be on the point of rupturing. It was opened to relieve the tension and closed at once. Apparently the transverse colon had been hanging down in the abdomen and a long loop had apparently twisted on itself. Reversal of the colon immediately relieved the obstruction. The operation was completed by colostomy and the patient made an uneventful recovery. The colostomy will be closed subsequently by a plastic operation.

MESENTERIC CYSTS

DR. WILLIAM B. SWARTLEY read a paper with the above title, for which see page 886.